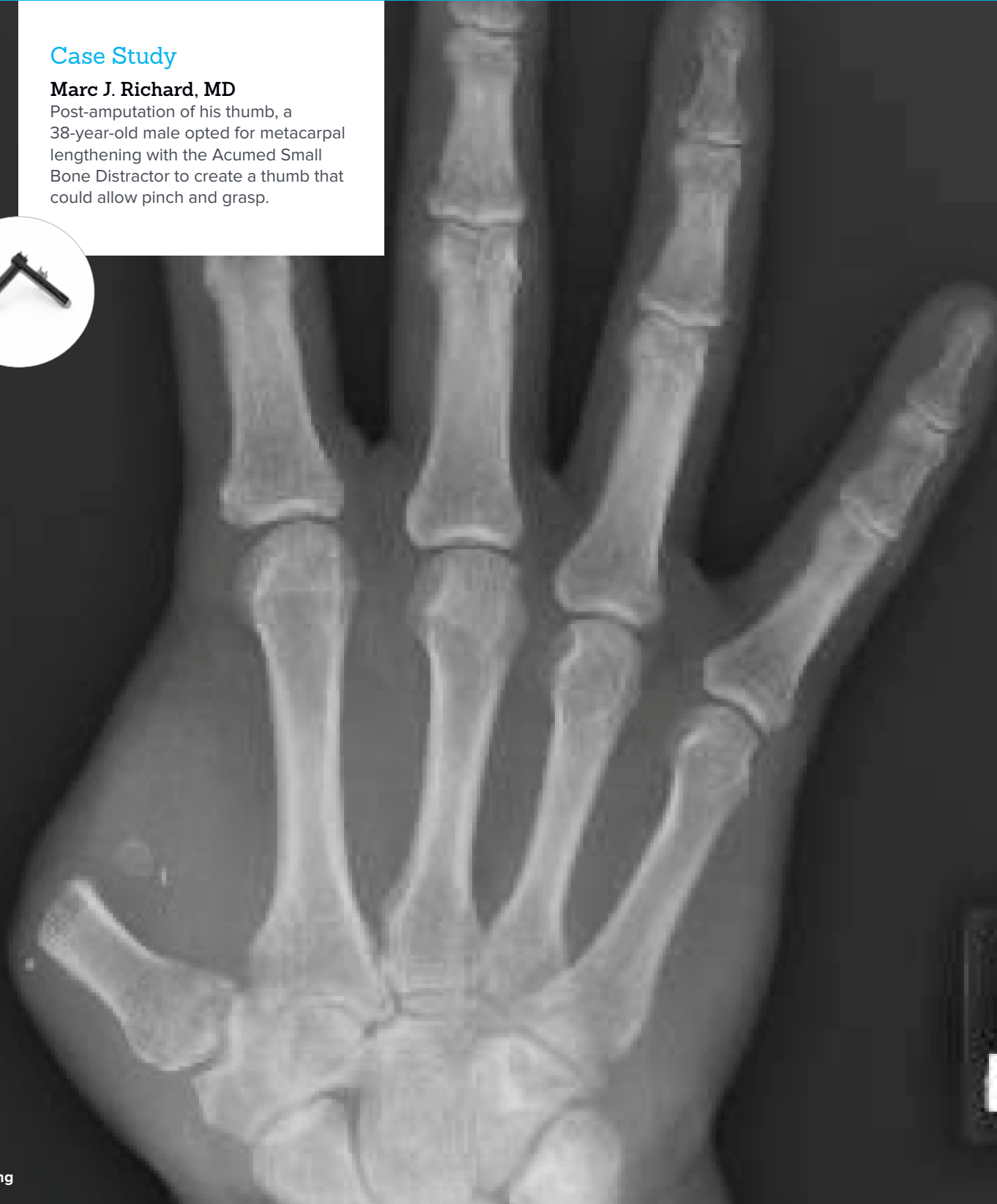


Metacarpal Lengthening Using Distraction Osteogenesis

Case Study

Marc J. Richard, MD

Post-amputation of his thumb, a 38-year-old male opted for metacarpal lengthening with the Acumed Small Bone Distractor to create a thumb that could allow pinch and grasp.

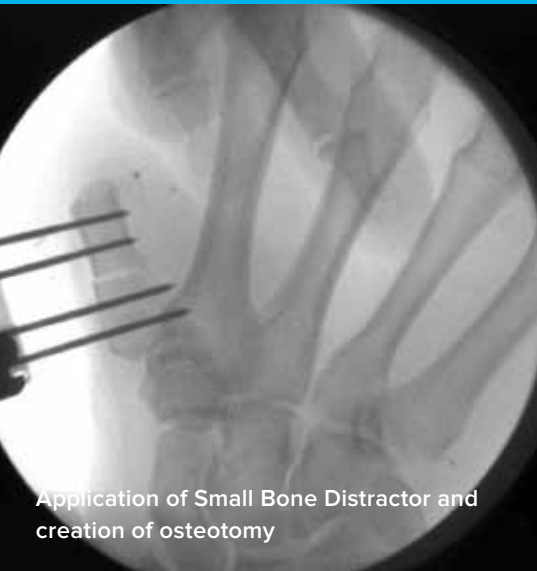

Acumed® is a global leader of innovative orthopaedic and medical solutions.

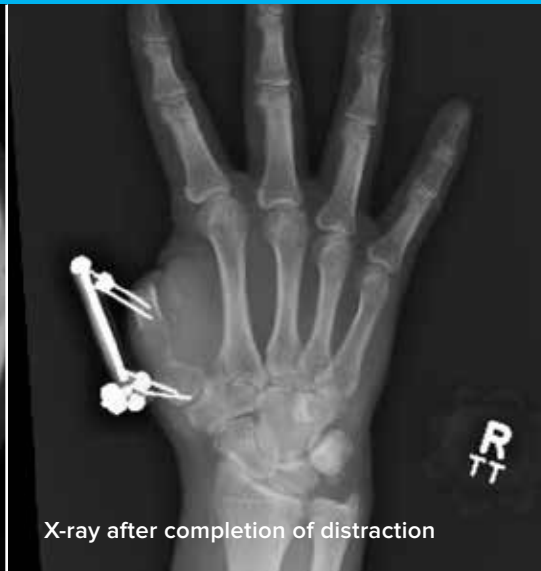

We are dedicated to developing products, service methods, and approaches that improve patient care.

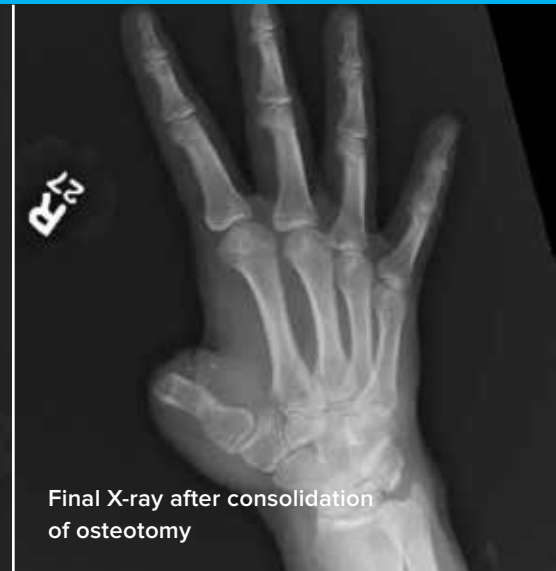Case Study | Marc J. Richard, MD



Application of Small Bone Distractor and creation of osteotomy



X-ray after completion of distraction



Final X-ray after consolidation of osteotomy

Metacarpal Lengthening Using Distraction Osteogenesis

Patient History

A 38-year-old, right-hand-dominant male sustained a thumb amputation in a blender. The thumb was not appropriate for replantation and he ultimately underwent a revision amputation through the distal aspect of the metacarpal. The patient was limited by the inability to grasp and pinch on his dominant hand. Once the soft tissue envelope was healed, the patient was presented with the surgical options for creating a thumb that could allow pinch and grasp. Given his level of amputation, he was offered a toe-to-thumb transfer or a metacarpal lengthening. He chose a metacarpal lengthening using distraction osteogenesis with the Acumed Small Bone Distractor.

Treatment

The patient was taken to the operating room for application of the Small Bone Distractor and creation of a metacarpal osteotomy. The patient was placed supine on the operating table with a hand table attachment. The right upper extremity was prepped and draped in the usual sterile fashion. A digital block was performed. The incision was then planned over the first metacarpal with fluoroscopic guidance. The osteotomy was performed as close to the proximal metaphysis of the metacarpal as the frame allowed. The K-wires were placed bicortically, proximally and distally to the anticipated osteotomy using the Small Bone Distractor as a guide. A small longitudinal incision was made in line with the metacarpal to expose the osteotomy site. Periosteal flaps were carefully preserved and elevated on the near cortex, but preserved intact over the other three cortices. A sagittal saw was then used to create an osteotomy and it was completed with an osteotome.

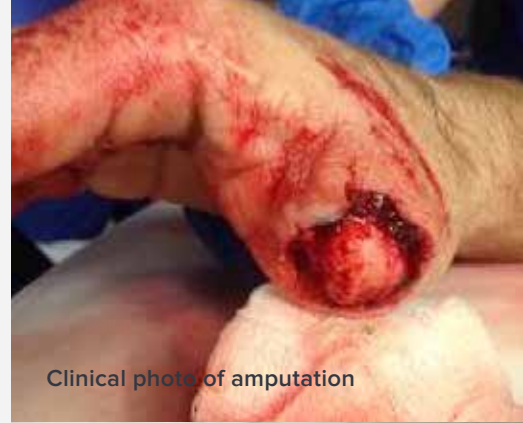The bone distractor was then secured to the K-wires. The skin incisions were closed with interrupted nylon sutures and the K-wires were cut to an appropriate length. The bone distractor hex was used to confirm appropriate travel along the distractor. It was then threaded into the storage location on the proximal distractor for future usage.

Postoperative Care

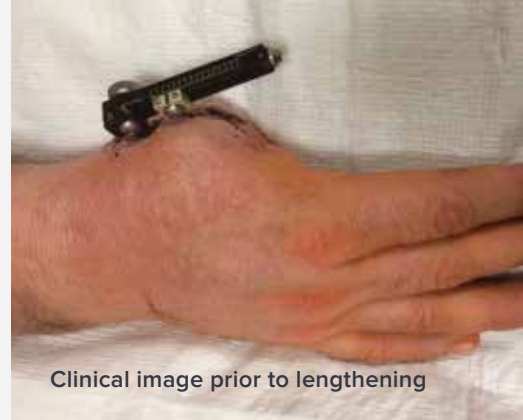The patient was seen in clinic on post-op day 3 for evaluation and teaching with respect to the lengthening protocol. Distraction osteogenesis is achieved by gradual lengthening of the bone at a rate of 1 mm/day. This is routinely accomplished by dividing the distraction into equal distractions of 0.25 mm every 6 hours. Because one complete revolution (360 degrees) results in 0.75 mm of lengthening, the patient was instructed to use the bone distractor hex to perform one-third of a revolution (120 degrees) 4 times each day. He was also instructed to perform routine pin care on the K-wires by cleansing the skin using a cotton-tipped swab soaked in a 1:1 mixture of sterile water and hydrogen peroxide. The patient was seen at 2 week intervals to confirm appropriate lengthening. When he reached the maximum lengthening allowed by the distractor (approximately 3 cm), he was instructed to stop the distraction process. The metacarpal osteotomy was allowed to consolidate with the bone distractor in place. At 13 weeks post-op, the X-rays and clinical examination confirmed appropriate consolidation of the osteotomy, and the distractor was removed in clinic. One month later, the patient was taken back to the operating room for a web space deepening to improve the apparent length of the thumb and to maximize its ability to function in prehensile grasp and pinch. An adjacent tissue rearrangement was performed. A K-wire was placed between the thumb and index metacarpals to preserve maximum abduction of the first web space. The K-wire was removed in clinic at 8 weeks post-op and the patient was referred to hand therapy for re-education and strengthening.

Discussion

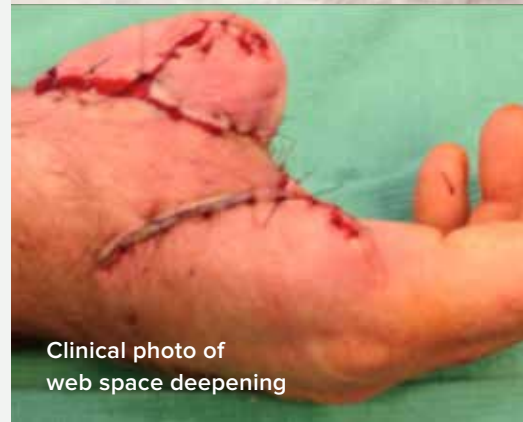Thumb amputation is a devastating injury that results in significant disability. The surgical options for the creation of a new thumb depend upon the level of amputation. In this case, the patient was a candidate for either a toe-to-thumb transfer or a metacarpal lengthening through distraction osteogenesis. While toe-to-thumb transfer is a good option for some patients, it is a technically demanding procedure that requires microsurgical skills and has a greater chance of donor site morbidity. In this case, the patient elected to have a metacarpal lengthening. The procedure is performed using the Acumed Small Bone Distractor. The device allows for 3 cm of lengthening which was enough for this patient to achieve an opposable post.



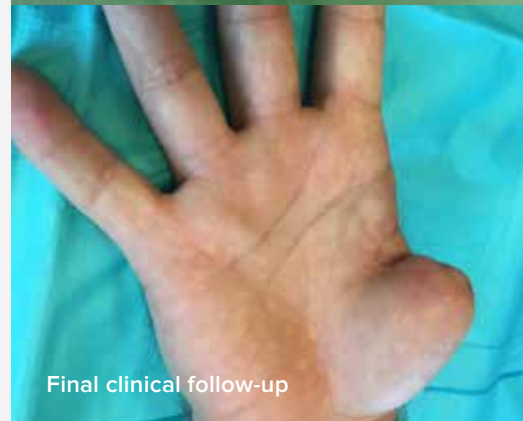Clinical photo of amputation



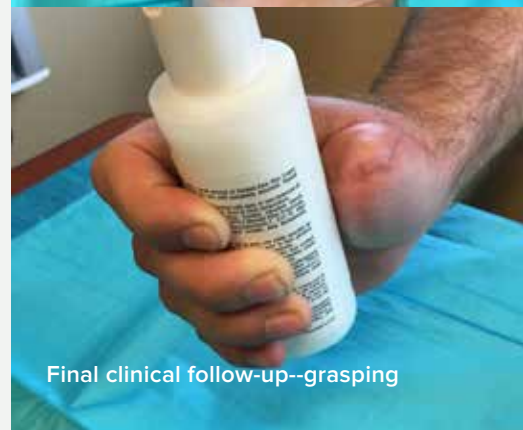Clinical image prior to lengthening



Clinical photo of web space deepening



Final clinical follow-up



Final clinical follow-up--grasping



HNW-70-08-A

Effective: 2016/12

© 2016 Acumed® LLC

Acumed® Headquarters
5885 NW Cornelius Pass Road
Hillsboro, OR 97124
Office: 888.627.9957
Fax: 503.520.9618
www.acumed.net

These materials contain information about products that may or may not be available in any particular country or may be available under different trademarks in different countries. The products may be approved or cleared by governmental regulatory organizations for sale or use with different indications or restrictions in different countries. Products may not be approved for use in all countries. Nothing contained on these materials should be construed as a promotion or solicitation for any product or for the use of any product in a particular way which is not authorized under the laws and regulations of the country where the reader is located. Specific questions physicians may have about the availability and use of the products described on these materials should be directed to their particular local sales representative. Specific questions patients may have about the use of the products described in these materials or the appropriateness for their own conditions should be directed to their own physician.

